



**PATIENT**

Arthur Smith

**SPECIES**

Canine

**BREED**

Beagle Mix

**SEX**

Male Neutered

**AGE**

2.10 years

**WEIGHT**

32.2lbs

**INTERPRETED BY**

Maggie Machen Lamy,  
DVM, DACVIM  
(Cardiology)

**IMAGING PERFORMED BY**

Goodman, DVM

**HOSPITAL NAME**

Evendale-Blue Ash Pet  
Hospital

**REFERRING VET**

Dr. Wehmer

**INVOICE**

47741

**DATE**

5/1/26

**PRESENTING CLINICAL SIGNS**

History: Seen by a Cardiologist in September 2025 and diagnosed with MVD stage B1. Possible grade 1/6 heart murmur. Asymptomatic. Elevated BNP: 1446pmol/L  
Prior echo results (M. McLane 9-25): very mild MV dysplasia; trace TR, trace MR

**ELECTROCARDIOGRAPHIC FINDINGS** \*Note: Single lead ECGs are evaluated as a rhythm strip. Morphology/MEA cannot be definitively commented on.

A single lead ECG is available; 25mm/s, 10mm/mV. The average heart rate is 100bpm. The rhythm is sinus in origin, with a p for every QRS complex and vice versa. The P and QRS morphologies are positive. No ectopic beats, pauses or other dysrhythmias observed. ECG diagnosis: Normal sinus rhythm with respiratory variation.

**ECHOCARDIOGRAM FINDINGS**

2D, m-mode, color flow and doppler imaging is available. Mild MV thickening with no prolapse into the left atrial lumen. No obvious mitral regurgitation with a normal left atrial dimension. Normal LV diameter with adequate myocardial function. The tricuspid valve appears normal with no tricuspid regurgitation. Normal right atrial and ventricular diameter and morphology indicating no overt evidence of pulmonary arterial hypertension. The pulmonic and aortic valves are normal in morphology and mobility. Normal pulmonic and aortic outflow velocities with laminar flow. No obvious aortic and trace pulmonic insufficiency. No pericardial or pleural effusion noted. No obvious cardiac masses.

**CARDIAC CHART**

CANINE CARDIAC PARAMETERS	MR VMAX (m/s)	TR VMAX (m/s)	LA/AO (Boon method)	LA/AO (Heart Base; Swe)	FS (%)	EF (%)	EPSS (cm)
NORMAL PARAMETER	4.5-5.5	<2.7	1.3	<1.6	28-40	40-100	<0.6
PATIENT	NA	NA	NM	1.3	47	90	0.3
CANINE CARDIAC PARAMETERS	HR (BPM)	AV VMAX (m/s)	PV MAX (m/s)	BODY WEIGHT (kg)	LA 2D short axis Base view (cm)	LVIDd Avg; 2D and m-mode short axis (cm)	LVIDs Avg; 2D and m-mode short axis (cm)
NORMAL PARAMETER	50-100	0.7-1.7	0.7-1.6	BELOW	BELOW	BELOW	BELOW
PATIENT	NM	1.5	0.9	14.6	1.9	3.0	1.6
*Normal chamber parameters expressed as a mean value (SD)				3	1.27 (5.3)	2.46 (2.46)	1.36 (5.5)
BODY WEIGHT DEPENDENT PARAMETERS				5	1.40 (4.5)	2.74 (5.2)	1.60 (4.7)
*Note: All measurements based upon multi-modal images and methods. An average value is reported.				10	1.50 (3.8)	3.27 (3.5)	2.06 (3.1)
				15	1.83 (2.0)	3.71 (2.4)	2.43 (2.1)
				20	2.02 (1.9)	4.14 (2.2)	2.80 (2.0)
				25	2.18 (2.4)	4.48 (2.9)	3.10 (2.5)
				30	2.33 (3.3)	4.83 (3.9)	3.39 (3.4)
				35	2.48 (4.3)	5.17 (5.0)	3.69 (4.5)
				40	2.62 (5.2)	5.48 (6.1)	3.96 (5.4)
				50	2.88 (7.1)	6.07 (8.3)	4.46 (7.4)

Adapted from June Boon, Veterinary Echocardiography, 1998  
Rishniw M and Hollis NE, J Vet Intern Med 2000; 14:429-435  
Hansson et al, Vet Rad and Ultrasound 2002  
Bonagura et al. Echocardiography: principles of interpretation, Vet Clin North Am 15:1177, 1995



## PATIENT

Arthur Smith

## SPECIES

Canine

## BREED

Beagle Mix

## SEX

Male Neutered

## AGE

2.10 years

## WEIGHT

32.2lbs

## INTERPRETED BY

Maggie Machen Lamy,  
DVM, DACVIM  
(Cardiology)

## IMAGING PERFORMED BY

Goodman, DVM

## HOSPITAL NAME

Evendale-Blue Ash Pet  
Hospital

## REFERRING VET

Dr. Wehmer

## INVOICE

47741

## DATE

5/1/26

## INTERPRETATION OF THE FINDINGS & FURTHER RECOMMENDATIONS

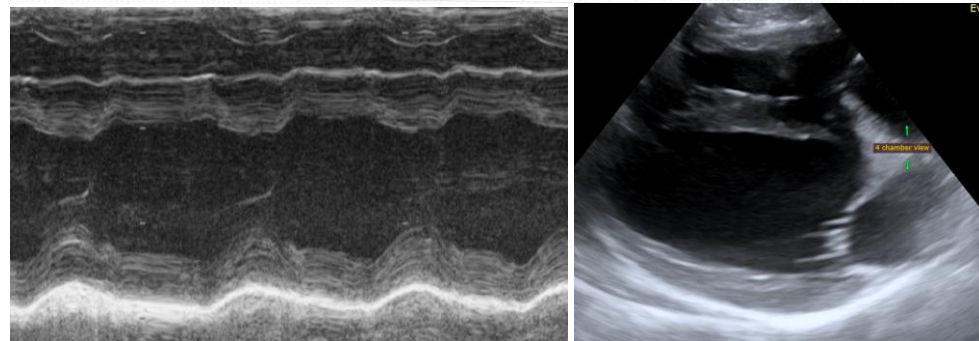
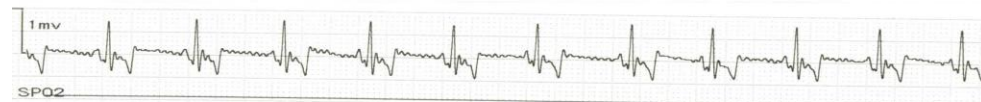
Overtly normal cardiac dimensions and function, with no obvious dysfunction or dilation of the left heart. No significant valvular leaks are visualized, and no evidence of pulmonary hypertension. The MV does appear mildly thickened; however, no MR nor TR are appreciated which is good news. The previous findings were/are likely subclinical and of little significance to this patient. The ECG is also normal, with a sinus rhythm.

No medications are indicated and the prognosis is open from a cardiac standpoint.

Monitor for development of a heart murmur, cough, labored breathing, exercise intolerance or collapse episodes.

A recheck echocardiogram is recommended should a significant murmur develop or signs of cardiac compromise be noted in the future.

## IMAGES



The information and recommendations provided are based on the images presented by the referring veterinarian. No evaluation can be communicated regarding pathology that was not visible in the image/video clips provided.

Thank you for this referral. This report was generated using transcription software, and minor dictation errors may be present. If the clinical or image interpretation does not parallel your findings or if I can be of any further assistance, please contact me.

**Maggie Machen Lamy, DVM**

**Diplomate of the American College of Veterinary Internal Medicine (Cardiology)**

info@sonopath.com